



KJS
Kosova Journal of Surgery

PACS
Pan-Albanian College of Surgeons



KOSOVA JOURNAL OF SURGERY

LIVER AND PANCREAS FOCUSED ISSUE

- ALBERTO FERRERES, RIFAT LATIFI, JOSÉ M RAMIA: Redefining the Scalpel: Past, Present, and Future Perspectives on the Surgical Management of Pancreatic Ductal Adenocarcinoma (PDAC)
- C. R. JÓDAR-SALCEDO; A. ROJAS-HOLGUÍN; D. LÓPEZ GUERRA; G. BLANCO-FERNÁNDEZ; JAÉN-TORREJIMENO: Arterial Resections in Pancreatic Cancer
- JOSÉ MANUEL RAMIA, MARIO SERRADILA, CELIA VILODRE, BELÉN HERNÁNDEZ, GERARDO BLANCO, CÁNDIDO ALCÁZAR: From ERPANDIS to SPANDISPAN: Two Decades of Collaborative Research in Left Pancreatectomy
- GUIDO PARQUET, ROSA SÁNCHEZ: Diagnostic and Therapeutic Approach to Acute Pancreatitis: Paraguayan National Consensus
- LINDSAY BARTHOLOME, RIFAT LATIFI: Nutritional Support in Severe Acute Pancreatitis: A Narrative Review
- DAI AILIN, REBEKAH YOUNG, VISHAL G. SHELAT: Severe Liver Trauma: Current Management

Volume 10, Issue 2
Liver and Pancreas
Focused Issue
August 2026
ISSN: 3027-5008 (Online)
ISSN: 3027-5016 (Print)

This journal is a joint publication of the Kosova College of Surgeons & University of Prishtina

www.kosovajournalofsurgery.net

Arterial Resections in Pancreatic Cancer

Jódar-Salcedo CR[1], Rojas-Holguín A[1,2], López Guerra D[1,2], Blanco-Fernández G[1,2], Jaén-Torrejimeno I[1].

[1] Department of HBP and Liver Transplant surgery, Hospital Universitario de Badajoz, Badajoz, Spain
[2] University of Extremadura. Departamento de Terapeútica Médico Quirúrgica. Facultad de Medicina y Ciencias de la Salud, Badajoz, Spain
Jódar-Salcedo CR: cristinarosel.jodar@salud-juntaex.es
Rojas-Holguín A: adela.rojas@salud-juntaex.es ORCID 0000-0002-6467-0658
López-Guerra D: diego.lopezg@salud-juntaex.es ORCID 0000-0001-9763-4402
Blanco-Fernández G: gerardoblanco@unex.es ORCID 0000-0003-4845-5306
Jaén-Torrejimeno I: isabel.jaen@salud-juntaex.es ORCID 0000-0001-6616-4807

Corresponding Author:

GERARDO BLANCO-FERNÁNDEZ, MD, PHD

Hepatobiliary Surgeon of the Department of HBP and Liver Transplant Surgery
Universidad de Extremadura.
Departamento de Terapeútica Médico Quirúrgica.
Facultad de Medicina y Ciencias de la Salud
Avda de Elvas s/n 06006 Badajoz, Spain
Tel. (+34) 9242218022, FAX (+34) 924219838
E-mail: gerardoblanco@unex.es

Abstract

At the time of diagnosis, only about 20% of patients with pancreatic adenocarcinoma are considered resectable. In a large proportion of cases, there is evidence of local vascular invasion, either venous or arterial. Traditionally, arterial resection combined with pancreatic surgery was considered a contraindication. However, with advances in modern chemotherapeutic regimens and increased experience in high-volume referral centers, it has been observed that, in expert hands, arterial resection can improve survival with only a mild increase in postoperative morbidity and mortality. Preoperative radiologic assessment is essential for evaluating arterial involvement and planning the most appropriate surgical approach. Appropriate patient selection is crucial to identify those who may benefit from this more aggressive oncologic surgical strategy.

Introduction

Pancreatic ductal adenocarcinoma (PDAC) is one of the most aggressive gastrointestinal malignancies, with a particularly poor prognosis. At the time of diagnosis, up to 50% of patients already have overt metastases, and only about 20% of tumors are considered resectable[1]. Radical surgical resection with negative margins (R0) remains the only potentially curative option[1,2].

In cases of locally advanced pancreatic adenocarcinoma (LA-PDAC), invasion of critical vascular structures is common, with venous involvement being the most

© 2026 The Author(s). Published by Kosova Journal of Surgery. This is an open access article distributed under the terms of the Creative Commons Attribution License (CC BY 4.0), which permits unrestricted use, distribution, and reproduction in any medium, provided the original work is properly cited.

frequent. Historically, this condition precluded curative surgical treatment. However, advances in neoadjuvant chemotherapy, surgical techniques, and perioperative care have led to the emergence of vascular resection as part of aggressive treatment strategies in selected cases[3].

Currently, the morbidity and mortality associated with pancreatectomy with venous resection are largely comparable to those of standard pancreatectomy. This has contributed to the acceptance of combined venous resection as a standard technique[3].

In contrast, arterial resection remains more controversial due to the highly variable arterial anatomy, the complexity of resection and revascularization procedures, and the risk of arterial occlusion, all of which may negatively impact surgical outcomes[4].

Indications and Selection Criteria

Traditionally, arterial invasion—particularly involving the superior mesenteric artery (SMA), celiac axis (CA), or common hepatic artery (CHA)—has been considered a contraindication to surgery due to its association with high morbidity and mortality, and poor oncologic outcomes[2].

With the introduction of neoadjuvant chemotherapy regimens such as FOLFIRINOX and gemcitabine plus nab-paclitaxel, sometimes combined with radiotherapy, patients with locally advanced (LA) or borderline resectable (BR) tumors have shown conversion to resectable disease with curative intent and negative margins (R0) in up to 30% of LA-PDAC cases[5].

In general, arterial resection should be evaluated within a multidisciplinary team setting and may be considered for patients with good performance status (ECOG 0–1), no metastatic disease, a favorable radiologic and metabolic response to neoadjuvant therapy, and a reasonable expectation of achieving an R0 resection[1].

A literature review has been performed about the resectability of pancreatic cancer based on the extent of arterial vascular invasion, the selection of candidates for vascular resection, and the evolution of surgical techniques aimed at achieving radical oncologic resection.

Patient Selection based on imaging data

A detailed evaluation using high-resolution imaging techniques is essential to determine resectability in pancreatic cancer with suspected arterial involvement. Imaging allows assessment of the degree of tumor–vessel contact, differentiation between compression and true invasion, and planning of the surgical strategy[6].

Recommended Imaging Techniques[7]

A) Multidetector computed tomography (CT) angiography (arterial and venous phases; triphasic CT):

This is the standard modality for vascular evaluation. It enables visualization of tumor contact with the SMA, CHA, and CA. Tumor–artery contact is commonly classified as:

- <180° of the arterial circumference: suggestive of contact without invasion
- ≥180°: suggestive of true arterial infiltration (Figure 1).

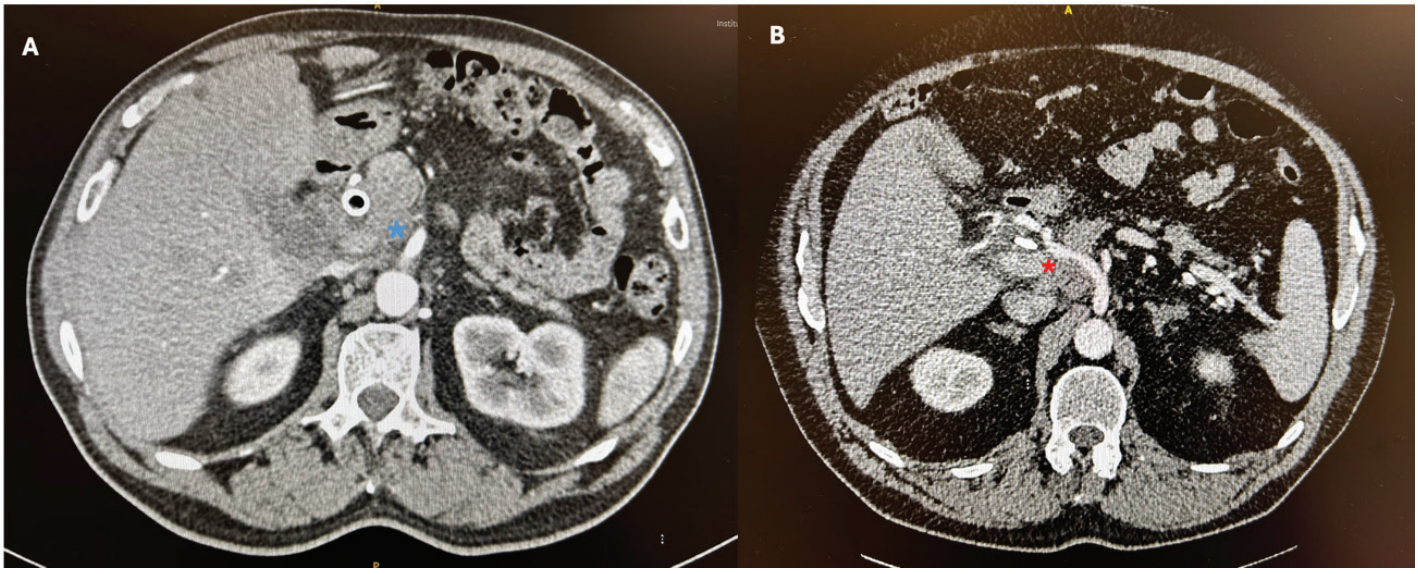

Figure 1: (A) CT scan showing <180° tumor contact with the superior mesenteric artery (SMA) (blue asterisk); (B) CT scan demonstrating involvement of the common hepatic artery (CHA) (red asterisk).

B) Magnetic Resonance Imaging (MRI) with contrast:

Useful in patients with iodine allergy or when CT findings are equivocal. Although it has lower spatial resolution for small vascular structures, it is valuable for assessing perineural spread and treatment response.

C) PET-CT:

It does not replace CT or MRI for anatomical assessment but may help detect occult metastatic disease and evaluate metabolic response after neoadjuvant therapy.

D) Endoscopic ultrasound (EUS):

Provides excellent resolution of peripancreatic structures but is operator-dependent and less useful for evaluating the entire vascular axis.

Radiological Criteria for Unresectability

Given the well-established high lethality of pancreatic ductal adenocarcinoma (PDAC), assessing resectability at the time of diagnosis is a priority to establish an appropriate therapeutic strategy. In fact, up to 50% of patients are considered unresectable at diagnosis despite the absence of distant metastases (8). For this purpose, an adequate imaging work-up using triphasic computed tomography (CT) with thin slices (1–2 mm) is essential to allow a detailed assessment of vascular involvement[9].

Based on anatomical and radiological criteria, unresectability can be defined in two distinct scenarios: locally advanced disease (LA-PDAC) and metastatic disease (M-PDAC) [9].

Regarding borderline resectable (BR) disease, this concept was first introduced in 2006 by the National Comprehensive Cancer Network (NCCN). It was defined as patients with PDAC who are at high risk for margin-positive resection and for whom neoadjuvant therapy should be considered. Since then, several groups, including the MD Anderson Cancer Center (MDACC) (10), NCCN, and the Intergroup Alliance[11], have proposed different definitions of BR-PDAC.

The concepts of unresectable (UR) and borderline resectable (BR) disease in LA-PDAC have evolved over time due to improvements in surgical techniques and the development and consolidation of neoadjuvant therapies. Consequently, during the 20th meeting of the International Association of Pancreatology (IAP), held in Sendai, Japan, in 2016, an international consensus was established to define resectable, unresectable (UR), and borderline resectable (BR) PDAC. These definitions were based on previously established criteria from the Japan Pancreas Society (JPS, 7th edition), the Intergroup Alliance, and the NCCN (2016 version)[9] (Table 1). In rare cases involving the origin of the celiac axis (CA), a distal pancreatectomy (body–tail resection) combined with potential celiac axis resection and preservation of the gastroduodenal arcade (modified Appleby procedure) may be considered[9,12].

Regarding borderline resectable (BR) disease, a subclassification was established based on the presence of isolated venous involvement (BR-PV) or arterial involvement (BR-A) (Table 2):

Table 1: Anatomical criteria for tumor unresectability established by consensus

LA-PDAC*	M-PDAC
- Tumor-related venous invasion with complete occlusion - Arterial contact/invasion ≥180° involving the superior mesenteric artery (SMA) or celiac axis (CA) - Extensive involvement of the common hepatic artery (CHA) with extension to the proper hepatic artery (PHA) or celiac axis (CA) - Aortic invasion or tumor contact with the aorta	- Metastatic disease - Distant para-aortic or extra-abdominal lymph node involvement (>10 mm in diameter on CT)

*With the exception of cases with ≥180° involvement of the origin of the celiac axis (CA) in which a distal pancreatectomy (body–tail resection) with potential celiac axis resection and preservation of the gastroduodenal arcade (modified Appleby procedure) may be feasible.

Table 2: Anatomical criteria for borderline resectability

BR-PV (SMV/PV involvement alone)	BR-A (arterial involvement)
- SMV/PV contact ≥180º or - bilateral narrowing/occlusion not exceeding the inferior border of the duodenum	- SMA, CA: tumor contact of less than 180º without showing deformity/stenosis - CHA: tumor contact, without showing tumor contact of the proper hepatic artery (PHA) and/or CA.

(Aortic involvement is categorized as unresectable. Presence of variant arterial anatomy is not taken into consideration)

Following the 2017 international consensus, in addition to the previously described anatomical and radiological criteria, Isaji et al.[9] also incorporated biological and conditional factors into the definition of BR-PDAC:

- **Biological definition of BR-PDAC (IAP, 2016):** Anatomically potentially resectable tumors with clinical findings suspicious, but not confirmed, for distant metastasis. These include elevated CA 19-9 levels (>500 U/mL) or regional lymph node metastases identified by biopsy or PET-CT.
- **Conditional definition of BR-PDAC (IAP, 2016):** Patients with anatomically resectable PDAC but with a performance status ≥2 are classified as BR-PDAC.

NCCN Classification of Resectability[13]

The anatomical classification of pancreatic cancer according to the National Comprehensive Cancer Network (NCCN) guidelines (version 1.2026) defines three categories based on the tumor's relationship to the major vascular structures. This categorization has direct implications for the therapeutic strategy at diagnosis (upfront surgery, neoadjuvant treatment, or palliative care).

1. Resectable

- **Arteries (SMA, CA, CHA):** no tumor contact.
- **Veins (portal vein [PV], superior mesenteric vein [SMV]):** no contact, or ≤180° contact without contour irregularity.
- **Clinical implication:** candidates for upfront surgery following preoperative evaluation.

2. Borderline Resectable (BRPC)

Arterial involvement:

Pancreatic head/uncinate process:

- **SMA:** tumor contact ≤180°, without deformity or significant stenosis.
- **CA:** tumor contact ≤180°, without involvement of the origin or aortic extension.
- **CHA:** tumor contact without involvement of the segment between the gastroduodenal artery (GDA) and the celiac trunk (CT), and without extension to the bifurcation; reconstruction is feasible.
- **Variant arterial anatomy:** tumor contact with variant arterial anatomy (e.g., accessory right hepatic artery, replaced right hepatic artery, replaced CHA, or the origin of replaced/accessory arteries) should be documented, as it may impact surgical planning.

Pancreatic body/tail:

- Tumor contact with the CA ≤180°.

Venous involvement (SMV or PV):

- Tumor contact >180°, or ≤180° with contour irregularity. Occlusion or thrombosis may or may not be present, but the vessel remains technically resectable and reconstructible.
- Tumor contact with the inferior vena cava (IVC).

Clinical implication: indication for neoadjuvant therapy prior to surgery with curative intent.

3. Locally Advanced / Unresectable

Arterial involvement:

Pancreatic head/uncinate process:

- Solid tumor contact >180° with the SMA or CA.

Pancreatic body/tail:

- Solid tumor contact >180° with the SMA or CA.
- Solid tumor contact with the CA and aortic involvement.

Venous involvement:

- Not amenable to resection and primary reconstruction due to complete occlusion of the SMV/PV.

Clinical implication: indication for systemic therapy (chemotherapy ± radiotherapy), with the possibility of surgical conversion in cases of favorable response.

Role of Assessment After Neoadjuvant Therapy

This classification should be reassessed after neoadjuvant therapy using a multidisciplinary team approach, as resectability may improve with treatment. Post-neoadjuvant imaging assessment can be challenging because inflammatory changes or chemotherapy-induced fibrosis may mimic persistent tumor[14]. In such cases, the concept of "biological resectability" should be considered. This concept, initially introduced by Katz et al.[11], refers to regression of vascular involvement or radiological stability, in association with a significant decrease in tumor markers[15,16].

According to the latest version of the NCCN guidelines for PDAC (version 1.2026), the criteria for resection include the following surgical principles: en bloc resection of the tumor and "at-risk" tissues to achieve complete tumor excision with negative margins (R0);

reestablishment of end-organ arterial inflow and venous outflow; restoration of gastrointestinal continuity; and adequate biliary drainage. These factors may ultimately be assessed intraoperatively, given the limited accuracy of conventional cross-sectional imaging in differentiating viable tumor tissue from fibrosis or scar tissue. This limitation may justify and support surgical exploration even in the presence of equivocal imaging findings[13].

Surgical exploration may be indicated in cases demonstrating regression or stability of arterial contact, absence of metastatic progression, and good clinical condition with a favorable metabolic response.

Technical Considerations of Arterial Resection during Pancreatectomy

As previously mentioned, the arteries most frequently involved are the common hepatic artery (CHA), celiac axis (CA), and superior mesenteric artery (SMA). Technical factors that have historically limited the adoption of pancreatic resection with arterial resection (P-AR) include the previously prohibitive mortality rates (up to 45%), mainly due to bleeding or thrombosis of reconstructed vessels, the frequent need for concomitant venous resection, and the requirement for advanced expertise in vascular surgery to perform arterial reconstruction[3,17].

However, with advances in surgical techniques and increasing experience, series from high-volume centers specializing in hepatobiliary and pancreatic surgery have demonstrated that P-AR can be performed safely, with acceptable morbidity, mortality, and overall survival rates.

In the series reported by Bachelier et al.[3], the rate of P-AR progressively increased over time, reaching approximately 10% of all pancreatic resections in the later study period. Despite the high complexity of the cases treated (>90% involving synchronous arterial and venous resections), the reported 90-day mortality rate (5.1%) was lower than that observed in post-discharge national databases of pancreatic resections in Germany (10.1%) and France (8.1%), as well as lower than rates reported in earlier P-AR series. These findings reflect the progressive evolution and continuous refinement of surgical techniques for combined arterial resection over the past two decades, as well as the impact of institutional policies aimed at reducing failure-to-rescue rates in high-volume pancreatic surgery centers[3].

Celiac Axis Resection

The modified Appleby technique allows resection of the celiac axis (CA) in tumors of the pancreatic body and tail (distal pancreatectomy with celiac axis resection, DP-CAR), taking advantage of retrograde blood flow from the superior mesenteric artery (SMA) through the posterior pancreaticoduodenal artery and the Haller arcade.

Preoperative assessment of collateral hepatic perfusion using CT angiography or Doppler ultrasound is essential. Celiac axis resection requires adequate collateral circulation via the SMA, pancreaticoduodenal arcade (PA), and gastroduodenal artery (GDA) to ensure sufficient hepatic arterial inflow. Therefore, involvement of these arteries during DP-CAR necessitates complex arterial reconstruction to prevent hepatic infarction. Given the morbidity and suboptimal outcomes associated with arterial reconstruction during pancreatic surgery, involvement of the SMA or GDA should be considered a contraindication to DP-CAR[18].

In cases where arterial clamping results in the absence of pulsation at the hepatic hilum, changes in liver color or consistency, or absence of intrahepatic arterial flow (as assessed by intraoperative Doppler ultrasound), reconstruction of the common hepatic artery (CHA) is recommended whenever feasible. Another clear indication for hepatic rearterialization is when a total pancreatectomy is performed for technical or oncological reasons[19].

Regarding reconstruction, after transection of the CA and CHA, extensive mobilization of the proximal and distal arterial ends is performed to allow a tension-free end-to-end anastomosis. If this is not feasible, interposition grafting may be performed using autologous vessels (such as the splenic, middle colic, or gastroepiploic arteries), cadaveric arterial graft (Figure 2) or synthetic grafts[19].

In some cases, preoperative embolization of the GDA is required to induce neovascularization, typically performed at least 10 days before surgery to allow adequate development of collateral circulation[18–20].

Hepatic Artery Resection

It may be indicated in cases of focal invasion of the proximal segment, particularly in pancreatic head tumors with extension towards the gastroduodenal artery (GDA).

During preoperative assessment, the presence of an accessory hepatic artery and whether the native hepatic artery is involved should be carefully evaluated. After hepatic artery resection, end-to-end anastomosis is often feasible due to the anatomical proximity to the celiac axis. In cases where primary anastomosis is not possible, graft interposition to the celiac trunk or abdominal

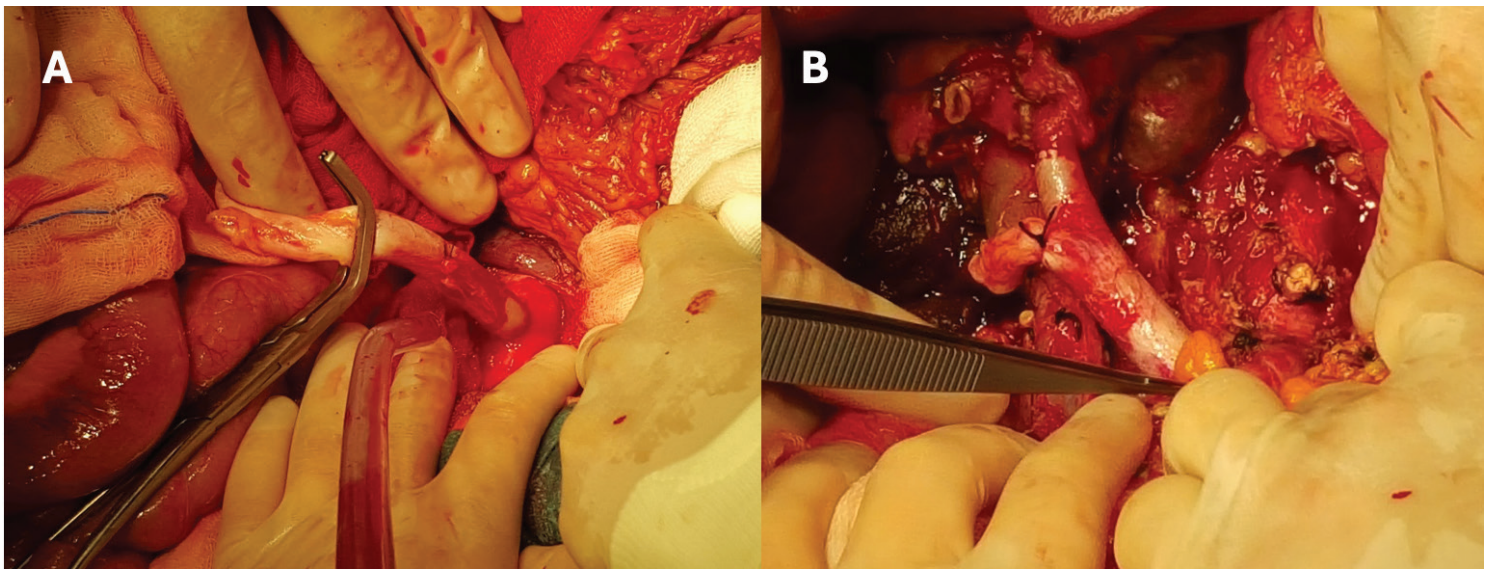

Figure 2: Intraoperative images of a modified Appleby procedure performed for a pancreatic neck–body adenocarcinoma involving the celiac trunk and common hepatic artery. A total splenoduodenopancreatectomy was carried out, and arterial reconstruction was achieved using a cadaveric iliac graft.

aorta is required. Preferred grafts for these anastomoses include the saphenous vein, gastric artery, mesenteric arterial branches, and splenic artery transposition[21].

Superior Mesenteric Artery Resection

Superior mesenteric artery (SMA) involvement is typically observed in lesions located predominantly in the uncinate process. This involvement is usually limited to the most distal portion of the artery. Proximal SMA involvement, close to its aortic origin, generally occurs in larger tumors in which the superior mesenteric vein (SMV) is also frequently infiltrated[19].

This represents the most technically demanding type of resection. It may be indicated only in highly selected cases with limited vascular invasion and a marked response to neoadjuvant therapy. Complication rates are high (including intestinal ischemia), and early series reported significant mortality, which initially limited its widespread acceptance.

Reconstruction techniques vary and include end-to-end anastomosis, use of prosthetic or biological patches, or en bloc resection with vascular bypass reconstruction[21].

Oncological and Perioperative Outcomes

Postoperative mortality rates after arterial resections have improved significantly (<5% in expert centers), which is closely associated with surgical experience and perioperative management optimization[22]. Even in high-volume pancreatic surgery centers, the perioperative morbidity rate for this high-risk procedure ranges from 25–59%, while postoperative mortality rates range from 10–16%[23].

In the systematic review by Noel et al., 2- and 3-year overall survival rates were 62.2% and 50.1%, respectively, in the arterial resection group compared with 55.7% and 49.8% in the non-arterial resection group[24]. In some cases, arterial resection does not correspond to histological arterial invasion. In the study by Yang et al., only 64.3% of cases demonstrated microscopic arterial infiltration[25].

R0 resection rates range between 60–80%, and median overall survival in patients undergoing resection after neoadjuvant therapy may reach 25–30 months, compared with 11–13 months in unresected patients[26]. Neoadjuvant chemotherapy has clearly contributed to reducing morbidity and mortality associated with arterial resection, as well as achieving higher R0 resection rates. Although residual tumor and extensive desmoplastic reaction surrounding the artery may complicate surgical dissection after neoadjuvant therapy, higher R0 rates have been achieved even in tumors initially considered locally advanced or unresectable at diagnosis[23].

Furthermore, expertise in vascular surgery and organ transplantation techniques supports the feasibility of the procedure, particularly for primary reconstruction or the use of vascular grafts[22].

The main prognostic determinants are the final resection status (R0 vs. R1), nodal status, and response to neoadjuvant

therapy. Patients with borderline resectable or locally advanced tumors exhibit higher rates of positive resection margins, leading to increased recurrence rates. Therefore, the use of more complex surgical techniques, including arterial resection, may enable the achievement of R0 resection, which is a key factor in improving prognosis[2,26].

Regarding postoperative complications associated with the surgical procedure, the main concern is clinically significant postoperative hemorrhage, which occurs in approximately 15% of patients.

Ischemic complications represent another inherent limitation of this technique, either due to interruption of arterial continuity when performed without reconstruction or due to thrombosis following arterial reconstruction. These complications have been reported to contribute to postoperative mortality in 45–73% of cases[27,28]. However, in the systematic review published by Noel et al. (2025), no increased rate of major complications (Clavien–Dindo ≥III) was observed with arterial resection (31.8% in the arterial resection group vs. 34.3% in the standard resection group)[24].

Another complication is refractory diarrhea resulting from gastrointestinal denervation following SMA dissection, which may hinder timely administration of adjuvant therapy and negatively impact patient survival[23].

Controversies and Future Perspectives

Arterial resection remains a controversial procedure due to the high rate of complications, particularly in historical series, suboptimal oncologic outcomes related to initial inadequate patient selection, and the technical complexity of the procedures. However, it is emerging as a valid strategy in carefully selected cases, especially with the support of neoadjuvant therapies and targeted treatments.

Recently, arterial preservation procedures have been proposed, employing specific techniques to maintain arterial lumen integrity while achieving oncologic radicality. These include periarterial divestment, periadventitial dissection, subadventitial divestment, and level 3 SMA dissection[29]. These emerging preservation approaches are based on histopathological evidence suggesting that true arterial wall invasion is relatively uncommon, as well as on the arterial wall's structural resilience, which may remain intact following aggressive periarterial dissection[23].

The incorporation of artificial intelligence, three-dimensional surgical planning, and advances in intraoperative perfusion techniques may further improve procedural safety and long-term outcomes.

Conclusion

Arterial resection in locally advanced pancreatic cancer can be considered no longer an absolute contraindication and represents an advance in aggressive oncologic surgery, reserved for carefully selected patients in highly specialized centers. Although technically demanding and associated with significant risks, it may offer improved survival in a subset of patients historically considered unresectable.

References:

1. Napoli N, Kauffmann E, Cacace C, Menonna F, Caramella D, Cappelli C, et al. Factors predicting survival in patients with locally advanced pancreatic cancer undergoing pancreatectomy with arterial resection. Updates Surg. 2021 Feb 1;73(1):233–49. doi:10.1007/s13304-020-00883-7 PubMed PMID: 32978753.

2. Wiltberger G, Bucher JN, Krenzien F, Benzing C, Atanasov G, Schmelzle M, et al. Extended resection in pancreatic metastases: Feasibility, frequency, and long-term outcome: A retrospective analysis. BMC Surg. 2015;15(1). doi:10.1186/s12893-015-0114-1 PubMed PMID: 26772176.

3. Bachellier P, Addeo P, Faitot F, Nappo G, Dufour P. Pancreatectomy With Arterial Resection for Pancreatic Adenocarcinoma: How Can It Be Done Safely and With Which Outcomes?: A Single Institution's Experience With 118 Patients. Ann Surg. 2020 May 1;271(5):932–40. doi:10.1097/SLA.0000000000003010 PubMed PMID: 30188399.

4. Alva-Ruiz R, Abdelrahman AM, Starlinger PP, Yonkus JA, Moravec DN, Busch JJ, et al. Patency rates of hepatic arterial resection and revascularization in locally advanced pancreatic cancer. HPB. 2022 Nov 1;24(11):1957–66. doi:10.1016/j.hpb.2022.06.005 PubMed PMID: 35780039.

5. Noda Y, Pisuchpen N, Mercaldo ND, Sekigami Y, Michelakos T, Parakh A, et al. Arterial involvement and resectability scoring system to predict R0 resection in patients with pancreatic ductal adenocarcinoma treated with neoadjuvant chemoradiation therapy. Eur Radiol. 2022 Apr 1;32(4):2470–80. doi:10.1007/s00330-021-08304-y PubMed PMID: 34665317.

6. Ahmed SA, Mourad AF, Hassan RA, Ibrahim MAE, Soliman A, Aboeleuon E, et al. Preoperative CT staging of borderline pancreatic cancer patients after neoadjuvant treatment: accuracy in the prediction of vascular invasion and resectability. Abdominal Radiology. 2021 Jan 1;46(1):280–9. doi:10.1007/s00261-020-02605-4 PubMed PMID: 32488556.

7. McKinney M, Griffin MO, Tolat PP. Multimodality Imaging for the Staging of Pancreatic Cancer. Surgical Oncology Clinics of North America. W.B. Saunders; 2021. p. 621–37. doi:10.1016/j.soc.2021.06.006 PubMed PMID: 34511186.

8. Floortje van Oosten A, Al Efishat M, Habib JR, Kinny-Köster B, Javed AA, He J, et al. Concepts and techniques for revascularization of replaced hepatic arteries in pancreatic head resections. HPB. Elsevier B.V.; 2023. p. 1279–87. doi:10.1016/j.hpb.2023.06.002 PubMed PMID: 37419779.

9. Isaji S, Mizuno S, Windsor JA, Bassi C, Fernández-del Castillo C, Hackert T, et al. International consensus on definition and criteria of borderline resectable pancreatic ductal adenocarcinoma 2017. Pancreatology. 2018 Jan 1;18(1):2–11. doi:10.1016/j.pan.2017.11.011 PubMed PMID: 29191513.

10. Varadhachary GR, Tamm EP, Abbruzzese JL, Xiong HQ, Crane CH, Wang H, et al. Borderline resectable pancreatic cancer: Definitions, management, and role of preoperative therapy. Annals of Surgical Oncology. 2006. p. 1035–46. doi:10.1245/ASO.2006.08.011 PubMed PMID: 16865597.

11. Katz MHG, Marsh R, Herman JM, Shi Q, Collison E, Venook AP, et al. Borderline resectable pancreatic cancer: Need for standardization and methods for optimal clinical trial design. Ann Surg Oncol. 2013 Aug;20(8):2787–95. doi:10.1245/s10434-013-2886-9 PubMed PMID: 23435609.

12. Haines M, Chua TC, Jamieson NB, Mittal A, Gill AJ, Samra JS. Pancreatoduodenectomy with Arterial Resection for Locally Advanced Pancreatic Cancer of the Head: A Systematic Review. Pancreas. Lippincott Williams and Wilkins; 2020. p. 621–8. doi:10.1097/MPA.0000000000001551 PubMed PMID: 32433398.

13. Ko AH, Malafa MP, Chair V, Cardin DB, Gabriela Chiorean E, Hutchinson Cancer Center Jared Christensen FA, et al. NCCN Guidelines Version 1.2026 Pancreatic Adenocarcinoma [Internet]. 2026. Available from: https://www.nccn.org/home/member-

14. Ferrone CR, Marchegiani G, Hong TS, Ryan DP, Deshpande V, McDonnell EI, et al. Radiological and surgical implications of neoadjuvant treatment with FOLFIRINOX for locally advanced and borderline resectable pancreatic cancer. In: Annals of Surgery. Lippincott Williams and Wilkins; 2015. p. 12–7. doi:10.1097/SLA.0000000000000867 PubMed PMID: 25599322.

15. Yamada S, Oshima K, Nomoto K, Sunagawa Y, Oshima Y, Nakao A. Reappraisal of the current resectability criteria and optimal treatment strategies for pancreatic cancer. J Gastrointest Oncol. 2024 Jun 30;15(3):1245–54. doi:10.21037/jgo-24-102

16. Fromer MW, Wilson KD, Philips P, Egger ME, Scoggins CR, McMasters KM, et al. Locally advanced pancreatic cancer: a reliable contraindication to resection in the modern era? HPB. 2022 Oct 1;24(10):1789–95. doi:10.1016/j.hpb.2021.09.002 PubMed PMID: 35491339.

17. Mollberg N, Rahbari NN, Koch M, Hartwig W, Hoeger Y, Büchler MW, et al. Arterial resection during pancreatectomy for pancreatic cancer: A systematic review and meta-analysis. Ann Surg. 2011;254(6):882–93. doi:10.1097/SLA.0b013e31823ac299 PubMed PMID: 22064622.

18. Sindayigaya R, Barat M, Tzedakis S, Dautry R, Dohan A, Belle A, et al. Modified Appleby procedure for locally advanced pancreatic carcinoma: A primer for the radiologist. Diagnostic and Interventional Imaging. Elsevier Masson s.r.l.; 2023. p. 455–64. doi:10.1016/j.diii.2023.05.008 PubMed PMID: 37301694.

19. Vicente E, Quijano Y, Ielpo B, Duran H, Diaz E, Fabra I, et al. ¿Sigue representando la infiltración arterial un criterio de irresecabilidad en el carcinoma de páncreas? Cir Esp. 2014;92(5):305–15. doi:https://doi.org/10.1016/j.ciresp.2013.11.001

20. Ramia JM, de Vicente E, Pardo F, Sabater L, Lopez-Ben S, Quijano M Y, et al. Preoperative hepatic artery embolization before distal pancreatectomy plus celiac axis resection does not improve surgical results: A Spanish multicentre study. Surgeon. 2021 Oct 1;19(5):e117–24. doi:10.1016/j.surge.2020.08.012 PubMed PMID: 33023848.

21. Kaya K, Mungan U. Multiple vascular reconstructions during pancreatectomy: Surgical techniques and strategies. Vascular. 2023 Oct 1;31(5):861–7. doi:10.1177/17085381221091053 PubMed PMID: 35477336.

22. Xue K, Huang X, Zhao P, Zhang Y, Tian B. Perioperative and long-term survival outcomes of pancreatectomy with arterial resection in borderline resectable or locally advanced pancreatic cancer following neoadjuvant therapy: a systematic review and meta-analysis. Int J Surg. 2023 Dec 1;109(12):4309–21. doi:10.1097/JS9.0000000000000742 PubMed PMID: 38259002.

23. Miao Y, Cai B, Lu Z. Technical options in surgery for artery-involving pancreatic cancer: Invasion depth matters. Surg Open Sci. 2023 Mar 1;12:55–61. doi:10.1016/j.sopen.2023.03.001

24. Noel C, Azeez A, Du Preez A, Noel K. Arterial Resections in Pancreatic Cancer—An Updated Systematic Review and Meta-Analysis. Cancers. Multidisciplinary Digital Publishing Institute (MDPI); 2025. doi:10.3390/cancers17091540

25. Yang F, Wang X, Jin C, He H, Fu D. Pancreatectomy with Hepatic Artery Resection for Pancreatic Head Cancer. World J Surg. 2019 Nov 1;43(11):2909–19. doi:10.1007/s00268-019-05106-8 PubMed PMID: 31396672.

26. Wiltberger G, den Dulk M, Bednarsch J, Czigany Z, Lang SA, Andert A, et al. Perioperative and long-term outcome of en-bloc arterial resection in pancreatic surgery. HPB. 2022 Jul 1;24(7):1119–28. doi:10.1016/j.hpb.2021.12.003 PubMed PMID: 35078714.

27. Klompmaker S, De Rooij T, Korteweg JJ, Van Dieren S, Van Lienden KP, Van Gulik TM, et al. Systematic review of outcomes after distal pancreatectomy with coeliac axis resection for locally advanced pancreatic cancer. British Journal of Surgery. 2016;103(8):941–9. doi:10.1002/bjs.10148 PubMed PMID: 27304847.

28. Klompmaker S, Boggi U, Hackert T, Salvia R, Weiss M, Yamaue H, et al. Distal Pancreatectomy with Celiac Axis Resection (DP-CAR) for Pancreatic Cancer. How I do It. Journal of Gastrointestinal Surgery. 2018;1–7. doi:10.1007/s11605-018-3894-7

29. Habib JR, Kinny-Köster B, van Oosten F, Javed AA, Cameron JL, Lafaro KJ, et al. Periadventitial dissection of the superior mesenteric artery for locally advanced pancreatic cancer: Surgical planning with the "halo sign" and "string sign." Surgery (United States). 2021 May 1;169(5):1026–31. doi:10.1016/j.surg.2020.08.031 PubMed PMID: 33036782.