



KJS
Kosova Journal of Surgery

PACS
Pan-Albanian College of Surgeons



# KOSOVA JOURNAL OF SURGERY

## LIVER AND PANCREAS FOCUSED ISSUE

- ALBERTO FERRERES, RIFAT LATIFI, JOSÉ M RAMIA: Redefining the Scalpel: Past, Present, and Future Perspectives on the Surgical Management of Pancreatic Ductal Adenocarcinoma (PDAC)
- C. R. JÓDAR-SALCEDO; A. ROJAS-HOLGUÍN; D. LÓPEZ GUERRA; G. BLANCO-FERNÁNDEZ; JAÉN-TORREJIMENO: Arterial Resections in Pancreatic Cancer
- JOSÉ MANUEL RAMIA, MARIO SERRADILA, CELIA VILODRE, BELÉN HERNÁNDEZ, GERARDO BLANCO, CÁNDIDO ALCÁZAR: From ERPANDIS to SPANDISPAN: Two Decades of Collaborative Research in Left Pancreatectomy
- GUIDO PARQUET, ROSA SÁNCHEZ: Diagnostic and Therapeutic Approach to Acute Pancreatitis: Paraguayan National Consensus
- LINDSAY BARTHOLOME, RIFAT LATIFI: Nutritional Support in Severe Acute Pancreatitis: A Narrative Review
- DAI AILIN, REBEKAH YOUNG, VISHAL G. SHELAT: Severe Liver Trauma: Current Management

Volume 10, Issue 2
Liver and Pancreas
Focused Issue
August 2026
ISSN: 3027-5008 (Online)
ISSN: 3027-5016 (Print)

This journal is a joint publication of the Kosova College of Surgeons & University of Prishtina

www.kosovajournalofsurgery.net

# Pushing the Boundaries of Liver Resection in Non-Colorectal Non-Neuroendocrine Metastatic Disease

**Mario Serradilla Martín[1], José M. Ramia[2]**

[1] Department of Surgery, Hospital Universitario Virgen de las Nieves, Instituto de Investigación Biosanitaria ibs.GRANADA, School of Medicine, University of Granada, Granada, Spain
[2] Department of Surgery, Hospital General Universitario Dr. Balmis, ISABIAL, Miguel Hernández University, Alicante, Spain

**Corresponding Author:**

**MARIO SERRADILLA MARTÍN**

Department of Surgery, Hospital Universitario Virgen de las Nieves
Av. de las Fuerzas Armadas, 2, 18014 Granada, Spain
*E-mail:* mserradilla@ugr.es

**Abstract**

**Background:** The liver, after the lymph nodes, is the most common site of metastatic disease. Liver resection is well established for colorectal and neuroendocrine liver metastases, but its role in metastases from other, non-colorectal non-neuroendocrine primary tumors remains debated because of the rarity of cases, the heterogeneity of the primary tumors involved, and the scarcity of prospective trials.

**Objective:** To synthesize the available evidence on outcomes after liver resection for non-colorectal non-neuroendocrine liver metastases according to the primary tumor of origin, and to identify the clinical and technical factors most consistently associated with improved survival.

**Findings:** A narrative review of clinical series, systematic reviews, and meta-analyses indexed in PubMed/MEDLINE was performed, organized by primary tumor of origin. A recent systematic review and meta-analysis of 40 studies and 5,696 patients reported 3- and 5-year overall survival of 40% and 32%, respectively, after resection, with postoperative morbidity of 28% and 30-day mortality of 2%. Outcomes varied markedly by tumor of origin: 5-year overall survival exceeded 40% for breast cancer, gastrointestinal stromal tumor, and melanoma, but remained below 25% for gastric and pancreatic cancer. Across nearly all tumor types, negative resection margins, limited hepatic disease, a disease-free interval longer than 12 months, and a favorable response to systemic therapy were the factors most consistently associated with better survival.

**Conclusions and Relevance:** In carefully selected patients with limited hepatic disease, a favorable response to systemic therapy, and no uncontrolled extrahepatic disease, liver resection provides a clear survival benefit over non-surgical treatment and, in some subgroups, particularly breast cancer, gastrointestinal stromal tumor, and uveal melanoma, the possibility of long-term disease control. Because prospectively validated selection criteria are still lacking, the surgical decision should be individualized within a multidisciplinary team.

© 2026 The Author(s). Published by Kosova Journal of Surgery. This is an open access article distributed under the terms of the Creative Commons Attribution License (CC BY 4.0), which permits unrestricted use, distribution, and reproduction in any medium, provided the original work is properly cited.

**Keywords**
liver metastases; hepatectomy; surgical oncology; gastrointestinal stromal tumor; uveal melanoma

## Introduction

Malignant tumors tend to spread, and the liver, after the lymph nodes, is the most common site of metastasis from abdominal tumors, owing to its dual portal and arterial blood supply and its rich lymphatic network. Liver resection with curative intent for the treatment of metastatic disease has been described for more than a century and is now widely accepted. Technical advances, technological innovation, and improved patient selection have markedly increased the safety of liver surgery, pushing the boundaries of resectability even for extensive resections.

For colorectal liver metastases, liver resection is now the reference treatment, with 5-year survival ranging from 40 to 58%.[1] The management of neuroendocrine liver metastases is also well supported in the literature. However, the role of surgery in non-colorectal non-neuroendocrine liver metastases, an enormously heterogeneous group that includes digestive tumors such as gastric cancer or gastrointestinal stromal tumor, and non-digestive tumors such as breast cancer, melanoma, soft tissue sarcoma, germ cell tumors, ovarian cancer, renal cell carcinoma, or differentiated thyroid carcinoma, remains poorly defined. This is due to the relative rarity of cases, the wide variety of biological behaviors depending on the primary tumor, and the near-absence of prospective randomized studies to guide decision-making.[2-4]

The aim of this narrative review is to examine the available evidence on the usefulness of liver resection in non-colorectal non-neuroendocrine liver metastases, reviewing the published oncologic outcomes according to the primary tumor of origin, common prognostic factors, patient selection criteria, and relevant surgical technical aspects, including parenchymal-sparing techniques and minimally invasive approaches. Wherever possible, findings from the largest available series are cross-referenced against recently published, tumor-specific systematic reviews and meta-analyses, so that the conclusions of each section are grounded in quantifiable, reproducible evidence rather than in narrative impression alone.

## Methods

A narrative, non-systematic search of the literature indexed in PubMed/MEDLINE was conducted, combining the terms "liver resection," "hepatectomy," "liver metastases," "non-colorectal," and "non-neuroendocrine" with the names of the main primary tumors in this group (breast, gastric, gastrointestinal stromal tumor, melanoma, sarcoma, ovarian, testicular/germ cell, renal, and thyroid). Priority was given to large clinical series, systematic reviews, and meta-analyses published in English, without strict date limits given the scarcity of recent series in some subgroups; the search was last updated in September 2026 to add tumor-specific systematic reviews and meta-analyses through 2023, used throughout to corroborate and quantify the older primary series. Selection and synthesis were performed narratively by the authors, without a formal systematic protocol (no PRISMA diagram, dual independent screening, or risk-of-bias assessment); this remains a limitation of the work, addressed further in the Discussion.

## Patient selection criteria and prognostic factors

Unlike colorectal liver metastases, no prospectively validated selection criteria exist for non-colorectal non-neuroendocrine liver metastases. The largest multicenter series published to date, including 1,452 patients treated at French centers, reported 5- and 10-year overall survival (OS) of 36 and 23% respectively after resection, with low postoperative mortality, and identified ten independent prognostic factors that allowed the development of a risk model to help guide surgical indication.[1] This has since been corroborated at a population level by a meta-analysis pooling 40 studies and 5,696 patients, reporting 3- and 5-year OS of 40% and 32% after resection, with morbidity of 28% and 30-day mortality of 2%.[5] Factors consistently associated with worse prognosis include age over 60 years, a primary tumor other than breast, melanoma or squamous histology, a disease-free interval (DFI) under 12 months, extrahepatic disease, inability to achieve negative margins, and the need for a major hepatectomy.[1,2,6] Other relevant factors include elevated bilirubin, severe complications, multiple or bilobar lesions, and regional lymph node metastases from the primary tumor.

Overall, the best candidates for resection are patients with good performance status, controlled primary tumor, limited hepatic disease, no uncontrolled extrahepatic disease, favorable response or stability after systemic therapy, and a reasonable expectation of negative margins. The decision should be individualized within a multidisciplinary team (hepatobiliary surgery, medical oncology, interventional radiology), since no single criterion has

sufficient predictive capacity alone.[3,4] Figure 1 summarizes a proposed practical algorithm, derived from these criteria, for guiding patient selection, reflecting a composite, multidisciplinary assessment rather than reliance on any single threshold.

## Liver metastases of digestive origin

### *Gastric cancer*

Gastric cancer is among the most frequently diagnosed malignancies worldwide and an important cause of cancer mortality, largely because it is often diagnosed at an advanced stage.[7] With liver metastases, standard of care remains systemic chemotherapy (median survival about 12 months), but several meta-analyses show a survival benefit for hepatectomy versus non-surgical treatment at 1, 3, and 5 years in carefully selected patients.[8] Median survival after resection ranges 5-8 months in older series (1-year survival 15-50%, 5-year survival approximately 19%), with up to 39% 5-year survival for resected metachronous metastases with wide margins.[9] Lymph node status of the primary tumor is an important independent prognostic factor, with better outcomes in N0/N1 than N2/N3 disease.[10] Metachronous resection appears to outperform synchronous resection, and a single lesion with wide margins is likewise favorable. A larger, more recent meta-analysis of 55 studies and 1,990 patients corroborated these figures, reporting 5-year OS of 24.7% and median OS of 24.5 months after hepatectomy, with

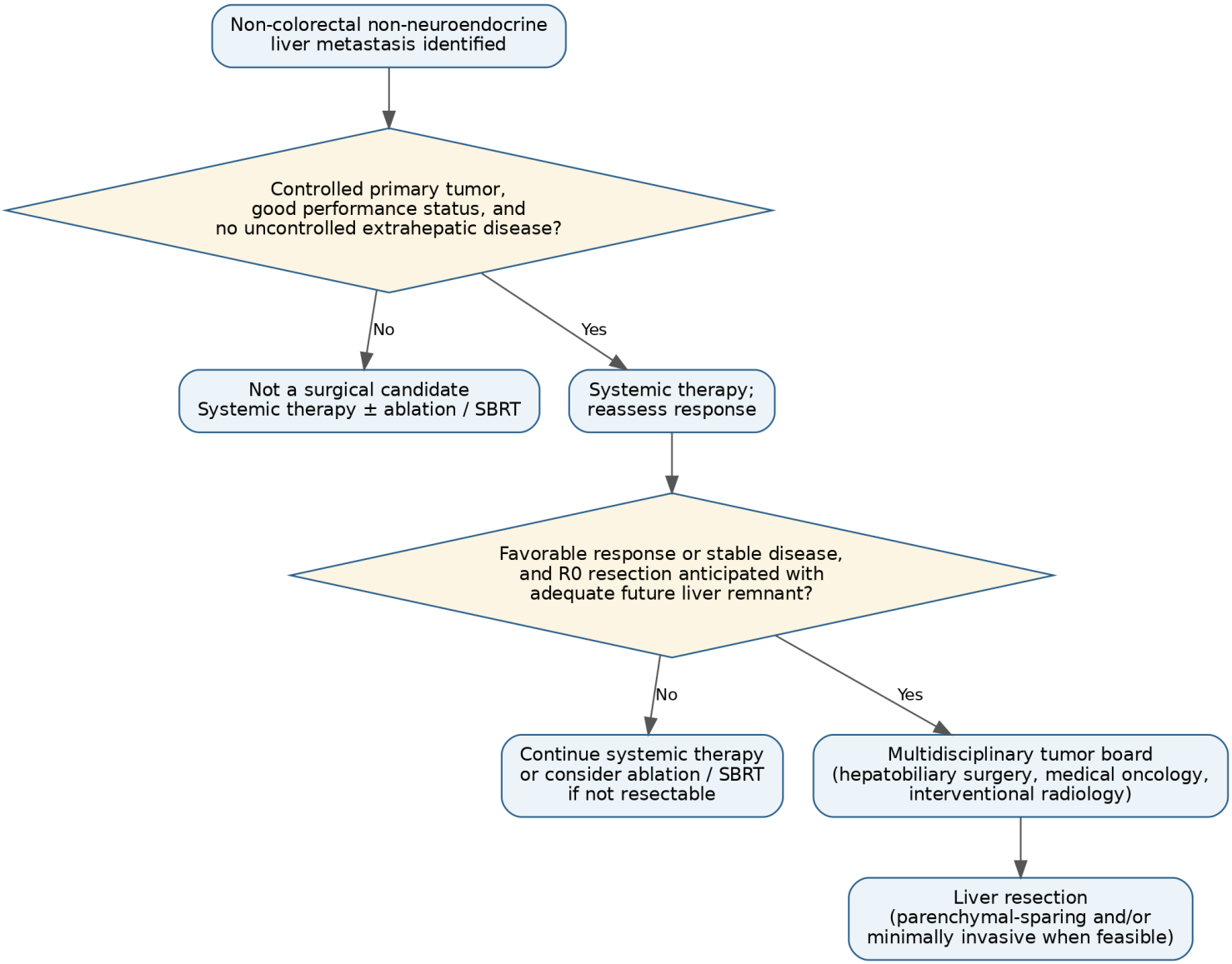


**Figure 1.** Proposed algorithm for the selection of candidates for liver resection in non-colorectal non-neuroendocrine liver metastases, based on control of the primary tumor, performance status, extrahepatic disease status, response to systemic therapy, and anticipated completeness of resection. SBRT, stereotactic body radiotherapy.

low 30-day mortality (1.4%); metachronous presentation, well- to moderately differentiated histology, small tumor size, early nodal stage, R0 resection, unilobar involvement, and solitary lesions predicted a favorable outcome.[11] Hepatectomy is therefore best regarded as a selective option for patients meeting several of these criteria, not as routine care.

### *Gastrointestinal stromal tumor*

Gastrointestinal stromal tumor (GIST) accounts for 1-3% of digestive neoplasms and is the most common mesenchymal tumor of the gastrointestinal tract; the liver and peritoneum are its most frequent metastatic sites.[12] Before tyrosine kinase inhibitors (TKI), resection was the only available treatment, with 5-year survival approximately 30% and median survival 36-47%.[13] Imatinib radically changed prognosis, with response rates up to 80%, though secondary resistance develops in roughly half of patients around two years into treatment, renewing interest in surgery as an adjunct to systemic therapy; surgical series report 5-year OS approximately 34%, with low morbidity and mortality (about 10% and 2%).[14] Postoperative TKI therapy is associated with the best outcomes, while extrahepatic disease at resection predicts worse survival.[15,16] Surgery has been proposed mainly for focal, early resistance within the first six months of treatment, to reduce the risk of selecting resistant clones.[17] A meta-analysis of 11 studies and 988 patients has since confirmed this benefit quantitatively: adding surgery to TKI therapy significantly reduced the risk of death compared with pharmacotherapy alone (hazard ratio 2.10, 95% CI 1.58–2.79), supporting a combined surgical and pharmacologic strategy in patients with focal, non-progressive disease.[18]

### *Pancreatic cancer*

Pancreatic ductal adenocarcinoma (PDAC) carries a particularly poor prognosis (overall 5-year survival below 8%), and the liver is its most common metastatic site. With synchronous liver metastases, median OS barely reaches 5 months with non-surgical treatment, and surgery has traditionally been contraindicated. Recent series of combined resection of the primary tumor and liver metastases in oligometastatic disease (usually ≤3 lesions) report postoperative morbidity around 45-50% and mortality below 5%, with 1-, 3-, and 5-year survival of 41%, 13%, and 7-8% — higher than with systemic treatment alone in selected patients responding to neoadjuvant chemotherapy.[19,20] These results, although modest, suggest a very selected subgroup with oligometastatic disease confined to the liver and a favorable response to systemic therapy might benefit from a combined approach; however, the lack of a validated definition of oligometastatic pancreatic disease and the single-center, retrospective nature of the available series preclude firm conclusions at present.

## Liver metastases of non-digestive origin

### *Breast cancer*

Breast cancer is the leading cause of cancer death in women worldwide, and the liver is the third most common site of metastasis after bone and lung.[21] Five-year survival for localized breast cancer exceeds 99%, but the development of untreated liver metastases drastically reduces prognosis, with median survival of 4 to 8 months. Systemic therapy remains the cornerstone of management of metastatic disease, and leading international guidelines recommend that local treatment of the liver, including surgery, be reserved for very selected patients with good performance status, limited hepatic disease, no extrahepatic lesions, and demonstrated disease control after systemic therapy, with no consensus on the optimal local technique among surgery, stereotactic radiotherapy, or intrahepatic chemotherapy.[22]

In the largest published series, liver resection was associated with 5-year OS of 41% and disease-free survival (DFS) of 21%, clearly superior to the 3-to-6-month median survival of untreated disease and to the approximately 15 months achieved with systemic therapy alone.[23] Factors associated with a better prognosis after resection include partial response to neoadjuvant chemotherapy, hormone receptor positivity, negative resection margins, a disease-free interval longer than 2 years, HER2 overexpression treated with targeted therapy, smaller tumor size, and unilobar disease, whereas prior failure of systemic therapy and a positive margin predict worse survival.[23-25] Careful intraoperative exploration is essential to avoid missing undetected disease, and both open and laparoscopic approaches have proven safe, with favorable results for the minimally invasive approach in selected patients. A 2023 meta-analysis of nine studies and 1,732 patients confirmed and quantified this benefit: 5-year OS was significantly better after resection than with non-surgical treatment (46.0% vs 24.7%; odds ratio 0.46, 95% CI 0.25–0.87), with an overall survival hazard ratio of 0.69 (95% CI 0.59–0.80) favoring surgery — among the most robust evidence for any tumor type in this review.[26]

### *Melanoma*

Uveal melanoma spreads exclusively via the hematogenous route, since the uveal tract lacks lymphatic vessels, and metastasizes in isolation to the liver in approximately half of patients.[27,28] Untreated hepatic disease carries a grim prognosis, with median survival of 4 to 6 months. Cutaneous melanoma, although sharing a melanocytic origin, spreads first via lymphatics to regional nodes and only later hematogenously, with the liver as its third most common visceral site; its liver metastases respond better to chemotherapy and checkpoint inhibitors than those of uveal origin, which has generated particular interest in local treatment, including surgery, for the latter.

Reference surgical series have reported complete resection of all measurable disease in approximately 75% of selected patients, with median OS of 27 to 29 months after surgery, compared with 6 months in patients treated non-surgically, and 2- and 5-year survival of 59 and 42% respectively in more recent series.[29-31] No relevant differences in survival have been observed according to the ocular or cutaneous origin of the primary melanoma once liver metastases are resected.[30] The prognostic factor most consistently associated with better survival is resection with disease-free margins, together with a lower number of liver lesions, a longer disease-free interval, a lower tumor burden, and the addition of systemic therapy. A pooled analysis of 912 patients with metastatic uveal melanoma from 29 prospective trials found substantially higher 1-year survival with liver-directed therapies, including resection, than with systemic therapy alone (57.2% vs 38.4%); elevated lactate dehydrogenase and alkaline phosphatase were the strongest adverse prognostic factors regardless of treatment.[32] Overall, surgical resection of melanoma metastatic to the liver, whether of uveal or cutaneous origin, can meaningfully prolong survival in highly selected patients, although subsequent hepatic recurrence is common.

### *Soft tissue sarcoma*

Liver metastases from soft tissue sarcoma are uncommon outside GIST. Small reference-center series report 5-year OS of approximately 30-31%, median survival of 24-46 months, and actuarial 1-, 3-, and 5-year survival of approximately 88-90%, 48-50%, and 30-32%.[13,33,34] Complete resection is the key determinant of prognosis, with 5-year survival dropping to single digits when disease is not completely resected.[13] Ideal candidates have good performance status, disease confined to the liver, a disease-free interval of at least 12 months, small tumor size, fewer than five resectable lesions, and no progression on prior systemic therapy; extrahepatic disease makes surgical benefit unlikely.[34] Comparing histologic subtypes, the best long-term outcomes are seen for GIST, followed by leiomyosarcoma and other sarcomas, although these series remain individually underpowered and heterogeneous, so the magnitude of benefit by subtype cannot be reliably estimated; decisions should rely more on histology-specific discussion than on sarcoma-wide statistics.[33]

### *Germ cell tumors and testicular cancer*

Liver metastases from germ cell tumors, particularly non-seminomatous testicular cancer, arise hematogenously and frequently coexist with retroperitoneal disease. Surgery on residual masses after chemotherapy is standard multimodal treatment, since such masses may contain necrotic tissue, mature teratoma, or viable tumor, each with distinct implications.[35] Complete resection has been associated with 3-year survival up to 78% in favorable series, though broader-criteria series report more modest 5-year survival of around 45%.[36,37] Residual mass size and primary histology help identify patients with a better prognosis, with worse outcomes for larger lesions. Evidence on liver metastases of testicular origin specifically remains confined to fewer than 30 patients across all published series combined, so larger studies are needed before surgery's role here is firmly established.

### *Ovarian cancer*

Ovarian cancer is frequently diagnosed at advanced stages and is a major cause of mortality among gynecologic cancers.[38] The liver may be affected by superficial peritoneal seeding or by true hematogenous spread; available series suggest somewhat better survival with peritoneal seeding.[39] Cytoreductive surgery, typically including hysterectomy, bilateral salpingo-oophorectomy, omentectomy, and resection of all visible disease, is the cornerstone of treatment for advanced disease, with liver resection as part of this procedure when parenchymal involvement is present.[40] Complete cytoreduction is associated with markedly better survival than suboptimal cytoreduction (median survival up to 65 months vs only a few months with substantial residual disease).[41] Liver resection combined with primary cytoreduction appears to yield better outcomes than when performed as secondary or salvage surgery.[39] Morbidity of liver resection within

cytoreductive surgery is acceptable in experienced centers, but because bilobar involvement is generally a contraindication and no data isolate the specific contribution of liver resection from the rest of the cytoreductive procedure, current evidence supports it mainly as a component of complete cytoreduction rather than as an independent intervention.[42]

### *Renal cell carcinoma*

Renal cell carcinoma comprises several histologic subtypes with distinct metastatic behavior; liver metastases are relatively uncommon compared with pulmonary, bone, or brain sites, and more frequent in the chromophobe subtype.[43] They account for approximately 5-8% of non-colorectal non-neuroendocrine liver metastases and carry a traditionally poor prognosis, usually multifocal; because the primary tumor responds only marginally to conventional chemotherapy and radiotherapy, resection has long been the only potentially curative option.[44] Single-center series report 5-year OS of 26-43% after resection, with median survival exceeding 10 years in the most favorable series; better prognosis is associated with male sex, tumor size under 5 cm, DFI over 24 months, and negative margins.[45] A meta-analysis of 17 studies of metastasectomy (including hepatic metastasectomy) in metastatic renal cell carcinoma corroborated this benefit, reporting significantly higher mortality without metastasectomy (hazard ratio 2.15, 95% CI 1.59–2.92), with clear-cell histology and prior nephrectomy as additional favorable factors.[46] Targeted therapy and immunotherapy have substantially changed systemic treatment over the past two decades, making it necessary to reassess surgery's role within a combined approach.[44]

### *Differentiated thyroid carcinoma*

Liver metastases from differentiated thyroid carcinoma are extremely rare, as this tumor behaves indolently and spreads preferentially to cervical nodes, lung, and bone; the literature is limited to very small series and isolated case reports. Distant metastases are the most important negative prognostic factor, with 10-year survival around 50% in disseminated disease.[47] When liver metastases do not take up radioactive iodine, which further worsens prognosis, surgical resection has been described as offering the best chance of prolonged survival in the isolated published cases, ahead of chemoembolization or

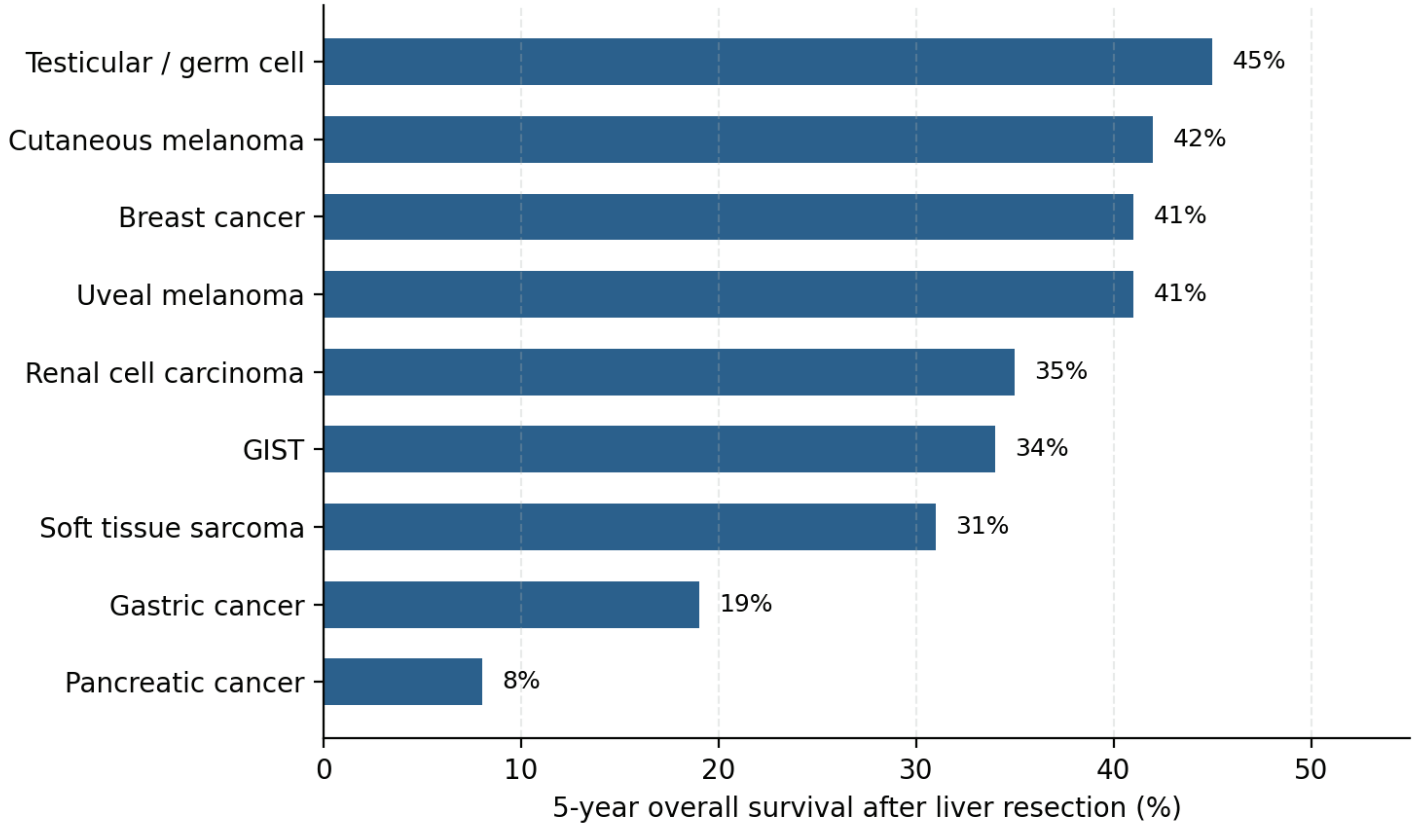


**Figure 2.** Reported 5-year overall survival (%) after liver resection, by primary tumor of origin. Values correspond to the midpoints or representative figures of the ranges reported in Table 1 and discussed in the text.

**Table 1. Summary of reported outcomes after liver resection for non-colorectal non-neuroendocrine liver metastases, by primary tumor of origin.**

| Primary tumor | 5-year OS (%) | Median survival (months) | Key favorable prognostic factors | Ref. |
|---|---|---|---|---|
| Breast cancer | 41 | ~40 | Partial response to neoadjuvant chemotherapy; hormone receptor positivity; R0 resection; DFI >2 years | 23,24,26 |
| Gastrointestinal stromal tumor | 34 | 36 | Postoperative TKI therapy; no extrahepatic disease at resection | 14,15,18 |
| Uveal melanoma | 40–42 | 27–29 | R0 resection; low tumor burden; longer DFI; addition of systemic therapy | 29-31,32 |
| Cutaneous melanoma | 42 | 27–29 | R0 resection; factors similar to uveal melanoma | 30 |
| Soft tissue sarcoma | 30–31 | 24–46 | Complete resection; DFI ≥12 months; fewer than 5 resectable lesions | 13,33,34 |
| Gastric cancer | 19–25 | 5–24 | Metachronous disease; N0/N1 nodal status; solitary lesion with wide margins; R0 resection | 8-10,11 |
| Renal cell carcinoma | 26–43 | often >60 | Male sex; tumor <5 cm; DFI >24 months; R0 resection | 45,46 |
| Ovarian cancer (as part of cytoreduction) | NR | up to 65* | Complete (R0) cytoreduction; primary rather than secondary setting | 39,41 |
| Germ cell / testicular tumors | 45–78 | NR | Small residual mass (<30 mm); favorable histology | 36,37 |
| Pancreatic cancer (oligometastatic) | 7–8 | ~12 | Oligometastatic disease (≤3 lesions); response to neoadjuvant chemotherapy | 19,20 |

OS, overall survival; DFI, disease-free interval; TKI, tyrosine kinase inhibitor; R0, microscopically negative resection margin; NR, not consistently reported across series. *Median survival reported for complete (R0) cytoreduction including liver resection. Figures are approximate and derived from the heterogeneous retrospective series and meta-analyses discussed in the corresponding sections of the text.

radiofrequency ablation. However, this entire evidence base consists of small retrospective series and case reports, none exceeding a handful of patients, with no comparative or prospective data; no recommendation stronger than individualized, case-by-case decision-making is currently justified for this tumor type.[48]

### Summary of reported outcomes

Table 1 summarizes the reported 5-year OS, median survival, and key favorable prognostic factors by primary tumor of origin, corroborated where available by recent tumor-specific meta-analyses. Figure 2 illustrates the corresponding 5-year OS graphically: outcomes are generally most favorable for germ cell tumors, melanoma, and breast cancer, and least favorable for gastric and pancreatic cancer, consistent with the pooled 5-year OS of 32% across all tumor types combined in the largest available meta-analysis.[5]

### Technical aspects of liver resection

Technical advances over the past two decades have expanded the indications for liver surgery across the whole spectrum of liver metastases. Parenchymal-sparing surgery, using limited atypical or segmental resections rather than major anatomic hepatectomies, preserves functional parenchyma, reduces the risk of postoperative liver failure, and facilitates a second intervention in case of recurrence, without compromising oncologic outcome when an adequate margin is achieved; this is particularly relevant for breast cancer and GIST, in which recurrence after a first resection is not uncommon and a second hepatectomy can again provide a survival benefit. The laparoscopic and, more recently, robotic approaches have been progressively incorporated into oncologic liver surgery, with favorable perioperative results and no evidence of oncologic harm compared with the open approach in experienced hands, including for breast cancer

and melanoma metastases, although the evidence derives predominantly from retrospective studies.

In extensive bilobar disease that would leave an insufficient liver remnant after a single resection, two-stage hepatectomy and, more recently, associating liver partition and portal vein ligation for staged hepatectomy have been used; the latter achieves much faster hypertrophy of the future remnant (one to two weeks) than conventional portal vein embolization, with resection rates up to 90-100% in colorectal disease. Its role in non-colorectal non-neuroendocrine liver metastases is far less studied and should be considered with particular caution, given its higher perioperative risk and the sometimes more aggressive biology of this group of tumors.

**Role of alternative local therapies**

In patients not candidates for resection because of technical factors, comorbidity, or lesion location, radiofrequency or microwave ablation and stereotactic body radiotherapy offer alternative local control, alone or combined with surgery, particularly in liver-metastatic uveal melanoma, where iterative treatments combining resection and ablation have achieved prolonged survival.[31,45] These techniques do not replace resection when it is technically feasible and oncologically reasonable, but they broaden options for non-surgical candidates; their role in this tumor group continues to evolve, with no randomized trials comparing both modalities to date.

**Discussion**

This review synthesizes the evidence on liver resection across ten non-colorectal non-neuroendocrine primary tumor types. In the largest available meta-analysis, resection achieved 3- and 5-year OS of 40% and 32%, with morbidity of 28% and 30-day mortality of 2%.[5] Outcomes were most favorable for breast cancer, GIST, and melanoma (5-year OS >40%, and up to 78% for selected germ cell tumor series) and least favorable for gastric and pancreatic cancer (approximately 20-25% and 7-8%). Negative margins, limited hepatic tumor burden, a disease-free interval exceeding 12 months, and a favorable response to systemic therapy were the factors most consistently associated with improved survival across tumor types.

These findings are directly confirmed by recent tumor-specific meta-analyses. For breast cancer, resection nearly doubled 5-year survival versus non-surgical treatment (46.0% vs 24.7%; hazard ratio 0.69, 95% CI 0.59–0.80).[26] For GIST, adding surgery to TKI therapy more than halved the risk of death versus pharmacotherapy alone (hazard ratio 2.10, 95% CI 1.58–2.79).[18] A similar effect size was reported for metastasectomy, including hepatic metastasectomy, in renal cell carcinoma (hazard ratio for death without metastasectomy 2.15, 95% CI 1.59–2.92).[46] Even gastric cancer, traditionally considered a poor surgical candidate, showed 5-year survival of 24.7% after hepatectomy in selected patients, challenging guidelines that discourage surgery in this setting.[11] This consistency across independently conducted meta-analyses strengthens confidence that the survival advantage attributed to resection reflects a genuine treatment effect and not only favorable patient selection, although residual confounding by indication cannot be excluded.

The variation in outcomes across tumor types most plausibly reflects differences in underlying biology rather than surgical technique. Breast cancer, GIST, and uveal melanoma tend toward indolent growth, organ-limited (often liver-only) spread, and, for breast cancer and GIST, effective systemic therapy capable of durable disease control around resection. Gastric and pancreatic adenocarcinoma are biologically more aggressive, with early micrometastatic dissemination that is frequently unrecognized at resection, likely explaining their persistently poor outcomes despite apparently complete clearance. The recurring prognostic value of a disease-free interval longer than 12 months across tumor types fits this framework, as it likely marks inherently less aggressive metastatic potential rather than being itself a modifiable target of treatment.

This review's strength is breadth: organizing fragmented, tumor-specific literature within one framework, cross-referenced against recent meta-analyses, provides an updated reference for a disease group individual centers rarely see in numbers sufficient to study alone. Its main limitation is methodological: a narrative, non-systematic review without a registered protocol, PRISMA-compliant search, dual screening, or risk-of-bias assessment, so selection cannot be considered free of the authors' judgment and publication bias cannot be excluded. Nearly all evidence is retrospective, from a few high-volume centers, with inherent selection bias since operated patients are by definition those judged fit for and likely to benefit from surgery; no randomized trial has compared resection with best systemic therapy for any tumor type discussed, and sample sizes for rarer tumors

(thyroid, testicular germ cell) remain in the dozens rather than hundreds of patients.

For practice, these findings support multidisciplinary consideration of resection when the primary tumor is controlled, hepatic disease is limited and resectable, extrahepatic disease is controlled, and systemic therapy has shown response or stability, weighting these criteria by the biology of the primary tumor. For research, the priority is prospective, multicenter or international registries with standardized eligibility and reporting criteria, allowing the comparative effectiveness of resection versus modern systemic therapy to be estimated with far less confounding than in today's retrospective series — of particular value for rarer subtypes unlikely ever to reach adequate single-center power.

## Conclusions

Non-colorectal non-neuroendocrine liver metastases are a biologically heterogeneous group of diseases, and the evidence reviewed here indicates that liver resection can provide prolonged survival and, in selected subgroups such as breast cancer, gastrointestinal stromal tumor, and uveal melanoma, the possibility of long-term disease control, in carefully selected patients with limited hepatic disease, a controlled primary tumor, no uncontrolled extrahepatic disease, and a favorable response to systemic therapy. Advances in systemic therapy and in parenchymal-sparing and minimally invasive surgical techniques have progressively broadened these indications while reducing perioperative morbidity. Because prospectively validated selection criteria remain lacking, the decision to proceed with resection should always be individualized within a multidisciplinary team, and further prospective, multicenter studies are needed to define more precisely which patients truly benefit from surgery within this heterogeneous group of diseases.

## Acknowledgments

None.

## Author contributions

M.S.M. and J.M.R. conceived and designed the review. M.S.M. performed the literature search and drafted the manuscript. J.M.R. critically revised the manuscript for important intellectual content. Both authors read and approved the final version and agree to be accountable for all aspects of the work.

## Funding

The authors declare that they received no specific funding for this work.

## Conflicts of interest

The authors declare no conflicts of interest related to the content of this manuscript.

## Informed consent

Not applicable: this work is a narrative review of the published literature and does not include original patient data.

## References:

1. Adam R, Chiche L, Aloia T, Elias D, Salmon R, Rivoire M, et al. Hepatic resection for noncolorectal nonendocrine liver metastases: analysis of 1,452 patients and development of a prognostic model. Ann Surg. 2006;244(4):524-535.

2. Harrison LE, Brennan MF, Newman E, Fortner JG, Picardo A, Blumgart LH, et al. Hepatic resection for noncolorectal, nonneuroendocrine metastases: a fifteen-year experience with ninety-six patients. Surgery. 1997;121(6):625-632.

3. Takemura N, Saiura A. Role of surgical resection for non-colorectal non-neuroendocrine liver metastases. World J Hepatol. 2017;9(5):242-251.

4. Del Basso C, Usai S, Levi Sandri GB. Non-colorectal non-neuroendocrine liver metastasis: a narrative review of surgical treatment. Chin Clin Oncol. 2022;11(4):28.

5. Ng KKC, Cheng NMY, Lok HT, et al. Is hepatic resection justified for non-colorectal non-neuroendocrine liver metastases? A systematic review and meta-analysis. Surgeon. 2023;21(3):160-172.

6. Elias D, Cavalcanti de Albuquerque A, Eggenspieler P, Plaud B, Ducreux M, Spielmann M, et al. Resection of liver metastases from a noncolorectal primary: indications and results based on 147 monocentric patients. J Am Coll Surg. 1998;187(5):487-493.

7. Smyth EC, Nilsson M, Grabsch HI, van Grieken NC, Lordick F. Gastric cancer. Lancet. 2020;396(10251):635-648.

8. Cui JK, Liu M, Shang XK. Hepatectomy for liver metastasis of gastric cancer: a meta-analysis. Surg Innov. 2019;26(6):692-697.

9. Miyazaki M, Itoh H, Nakagawa K, Ambiru S, Shimizu H, Togawa A, et al. Hepatic resection of liver metastases from gastric carcinoma. Am J Gastroenterol. 1997;92(3):490-493.

10. Oki E, Tokunaga S, Emi Y, Kusumoto T, Yamamoto M, Fukuzawa K, et al. Surgical treatment of liver metastasis of gastric cancer: a retrospective multicenter cohort study (KSCC1302). Gastric Cancer. 2016;19(3):968-976.

11. Conde Monroy D, Ibáñez-Pinilla M, Sabogal JC, et al. Survival outcomes of hepatectomy in gastric cancer liver metastasis: a systematic review and meta-analysis. J Clin Med. 2023;12(2):704.

12. Nishida T, Hirota S. Biological and clinical review of

stromal tumors in the gastrointestinal tract. Histol Histopathol. 2000;15(4):1293-1301.

13. DeMatteo RP, Shah A, Fong Y, Jarnagin WR, Blumgart LH, Brennan MF. Results of hepatic resection for sarcoma metastatic to liver. Ann Surg. 2001;234(4):540-548.

14. Nunobe S, Sano T, Shimada K, Sakamoto Y, Kosuge T. Surgery including liver resection for metastatic gastrointestinal stromal tumors or gastrointestinal leiomyosarcomas. Jpn J Clin Oncol. 2005;35(6):338-341.

15. Xia L, Zhang MM, Ji L, Li X, Wu XT. Resection combined with imatinib therapy for liver metastases of gastrointestinal stromal tumors. Surg Today. 2010;40(10):936-942.

16. Cavnar MJ, Seier K, Curtin C, Balachandran VP, Coit DG, Yoon SS, et al. Outcome of 1000 patients with gastrointestinal stromal tumor (GIST) treated by surgery in the pre- and post-imatinib eras. Ann Surg. 2021;273(1):128-138.

17. Machairas N, Prodromidou A, Molmenti E, Kostakis ID, Sotiropoulos GC. Management of liver metastases from gastrointestinal stromal tumors: where do we stand? J Gastrointest Oncol. 2017;8(6):1100-1108.

18. Rahimi-Ardabily A, Murdande S, Dong M, Gu KW, Zhang B, Miller K, et al. Liver resection for metastatic GIST tumor improves survival in the era of tyrosine kinase inhibitors: a systematic review and meta-analysis. Langenbecks Arch Surg. 2023;408:373.

19. Andreou A, Knitter S, Klein F, Malinka T, Schmelzle M, Struecker B, et al. The role of hepatectomy for synchronous liver metastases from pancreatic adenocarcinoma. Surg Oncol. 2018;27(4):688-694.

20. Hackert T, Niesen W, Hinz U, Tjaden C, Strobel O, Ulrich A, et al. Radical surgery of oligometastatic pancreatic cancer. Eur J Surg Oncol. 2017;43(2):358-363.

21. Hess KR, Varadhachary GR, Taylor SH, Wei W, Raber MN, Lenzi R, et al. Metastatic patterns in adenocarcinoma. Cancer. 2006;106(7):1624-1633.

22. Cardoso F, Paluch-Shimon S, Senkus E, Curigliano G, Aapro MS, André F, et al. 5th ESO-ESMO International Consensus Guidelines for advanced breast cancer (ABC 5). Ann Oncol. 2020;31(12):1623-1649.

23. Adam R, Aloia T, Krissat J, Bralet MP, Paule B, Giacchetti S, et al. Is liver resection justified for patients with hepatic metastases from breast cancer? Ann Surg. 2006;244(6):897-908.

24. He X, Zhang Q, Feng Y, et al. Resection of liver metastases from breast cancer: a multicentre analysis. Clin Transl Oncol. 2020;22(4):512-521.

25. Elias D, Maisonnette F, Druet-Cabanac M, Ouellet JF, Guinebretiere JM, Spielmann M, et al. An attempt to clarify indications for hepatectomy for liver metastases from breast cancer. Am J Surg. 2003;185(2):158-164.

26. Calpin GG, Davey MG, Calpin P, Browne F, Lowery AJ, Kerin MJ. The impact of liver resection on survival for patients with metastatic breast cancer: a systematic review and meta-analysis. Surgeon. 2023;21(4):242-249.

27. Jager MJ, Shields CL, Cebulla CM, Abdel-Rahman MH, Grossniklaus HE, Stern MH, et al. Uveal melanoma. Nat Rev Dis Primers. 2020;6(1):24.

28. Bustamante P, Piquet L, Landreville S, Burnier JV. Uveal melanoma pathobiology: metastasis to the liver. Semin Cancer Biol. 2021;71:65-85.

29. Rose DM, Essner R, Hughes TM, Tang PC, Bilchik A, Wanek LA, et al. Surgical resection for metastatic melanoma to the liver: the John Wayne Cancer Institute and Sydney Melanoma Unit experience. Arch Surg. 2001;136(8):950-955.

30. Ryu SW, Saw R, Scolyer RA, Crawford M, Thompson JF, Sandroussi C. Liver resection for metastatic melanoma: equivalent survival for cutaneous and ocular primaries. J Surg Oncol. 2013;108(2):129-135.

31. Mariani P, Piperno-Neumann S, Servois V, Berry MG, Dorval T, Plancher C, et al. Surgical management of liver metastases from uveal melanoma: 16 years' experience at the Institut Curie. Eur J Surg Oncol. 2009;35(9):1192-1197.

32. Khoja L, Atenafu EG, Suciu S, et al. Meta-analysis in metastatic uveal melanoma to determine progression free and overall survival benchmarks: an international rare cancers initiative (IRCI) ocular melanoma study. Ann Oncol. 2019;30(8):1370-1380.

33. Brudvik KW, Patel SH, Roland CL, Conrad C, Torres KE, Hunt KK, et al. Survival after resection of gastrointestinal stromal tumor and sarcoma liver metastases in 146 patients. J Gastrointest Surg. 2015;19(8):1476-1483.

34. Tirotta F, Hodson J, Parente A, Pasquali S, Sutcliffe R, Desai A, et al. Liver resection for sarcoma metastases: a systematic review and experience from two European centres. Eur J Surg Oncol. 2020;46(10 Pt A):1807-1813.

35. Rivoire M, Elias D, De Cian F, Kaemmerlen P, Theodore C, Fizazi K, et al. Multimodality treatment of patients with liver metastases from germ cell tumors. Cancer. 2001;92(3):578-587.

36. Maluccio M, Einhorn LH, Goulet RJ. Surgical therapy for testicular cancer metastatic to the liver. HPB (Oxford). 2007;9(3):199-200.

37. Hahn TL, Jacobson L, Einhorn LH, Foster R, Goulet RJ. Hepatic resection of metastatic testicular carcinoma: a further update. Ann Surg Oncol. 1999;6(7):640-644.

38. Nakayama K, Nakayama N, Katagiri H, Miyazaki K. Mechanisms of ovarian cancer metastasis: biochemical pathways. Int J Mol Sci. 2012;13(9):11705-11717.

39. Bacalbasa N, Dima S, Brasoveanu V, David L, Balescu I, Bacalbasa I, et al. Liver resection for ovarian cancer liver metastases as

part of cytoreductive surgery is safe and may bring survival benefit. World J Surg Oncol. 2015;13:235.

40. Pekmezci S, Saribeyoglu K, Aytac E, Karabork A, Baysal M, Onguru O, et al. Surgery for isolated liver metastasis of ovarian cancer. Asian J Surg. 2010;33(2):83-88.

41. Bristow RE, Tomacruz RS, Armstrong DK, Trimble EL, Montz FJ. Survival effect of maximal cytoreductive surgery for advanced ovarian carcinoma during the platinum era: a meta-analysis. J Clin Oncol. 2002;20(5):1248-1259.

42. Luna-Abanto J, García Ruiz L, Laura Martinez J, Alfredo Bravo Taxa M, Ruiz Figueroa E. Liver resection as part of cytoreductive surgery for ovarian cancer. J Gynecol Surg. 2020;36(2):70-75.

43. Dudani S, de Velasco G, Wells JC, Gan CL, Donskov F, Porta C, et al. Evaluation of clear cell, papillary, and chromophobe renal cell carcinoma metastasis sites and association with survival. JAMA Netw Open. 2021;4(1):e2021869.

44. Choueiri TK, Motzer RJ. Systemic therapy for metastatic renal-cell carcinoma. N Engl J Med. 2017;376(4):354-366.

45. Ruys AT, Tanis PJ, Nagtegaal ID, van Duijvendijk P, Verhoef C, Porte RJ, et al. Surgical treatment of renal cell cancer liver metastases: a population-based study. Ann Surg Oncol. 2011;18(7):1932-1938.

46. Hsieh PY, Hung SC, Li JR, et al. The effect of metastasectomy on overall survival in metastatic renal cell carcinoma: a systematic review and meta-analysis. Urol Oncol. 2021;39(7):422-430.

47. Elisei R, Molinaro E, Agate L, Bottici V, Masserini L, Ceccarelli C, et al. Are the clinical and pathological features of differentiated thyroid carcinoma really changed over the last 35 years? J Clin Endocrinol Metab. 2010;95(4):1516-1527.

48. Niederle B, Roka R, Schemper M, Fritsch A, Weissel M, Ramach W. Surgical treatment of distant metastases in differentiated thyroid cancer: indication and results. Surgery. 1986;100(6):1088-1097.